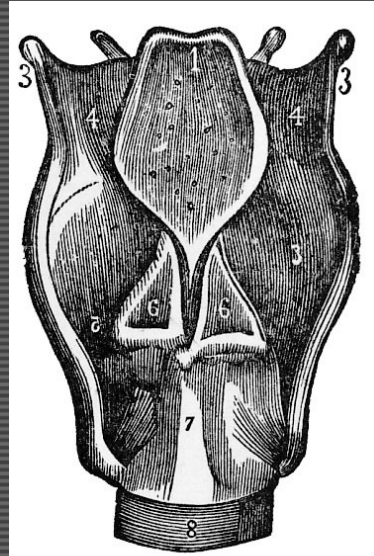


G22: Larynx



Group A: Pharynx (Cadaver Lab)

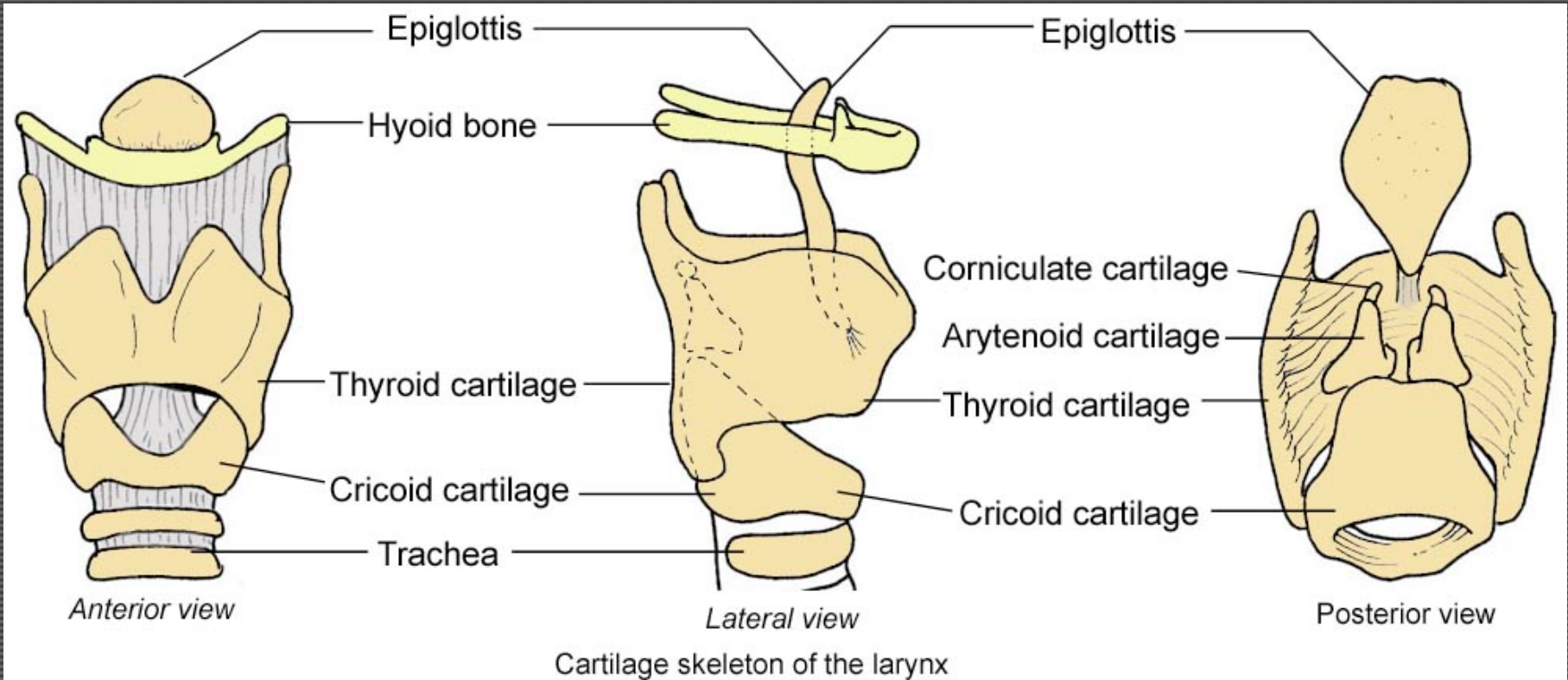
Group B: Clinical Apps (HSEB 1700)

Syllabus - Pg. 79

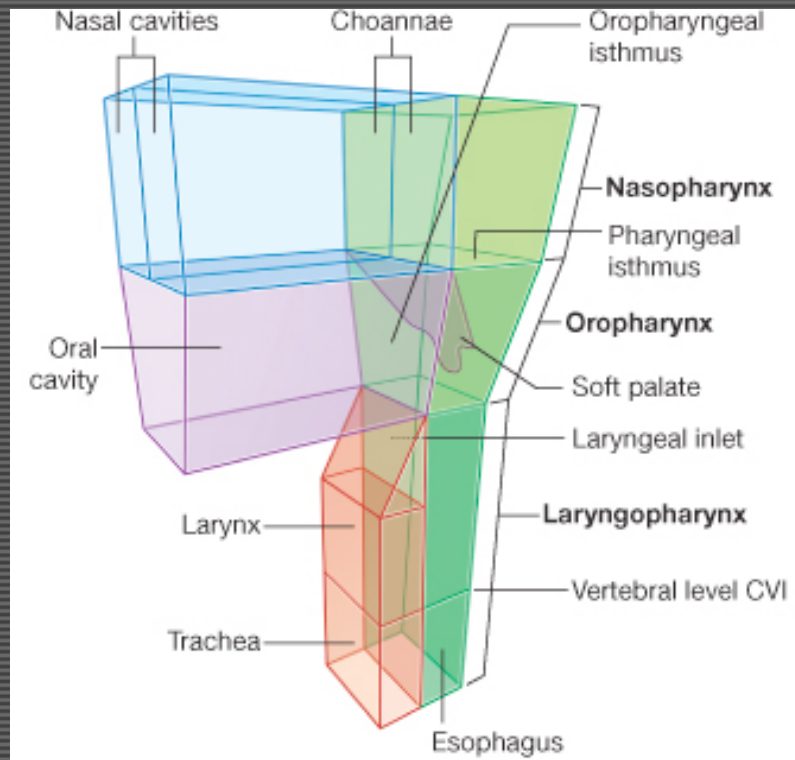
Objectives

1. Cartilaginous structure of the larynx
2. Musculature, blood supply and innervation of the larynx

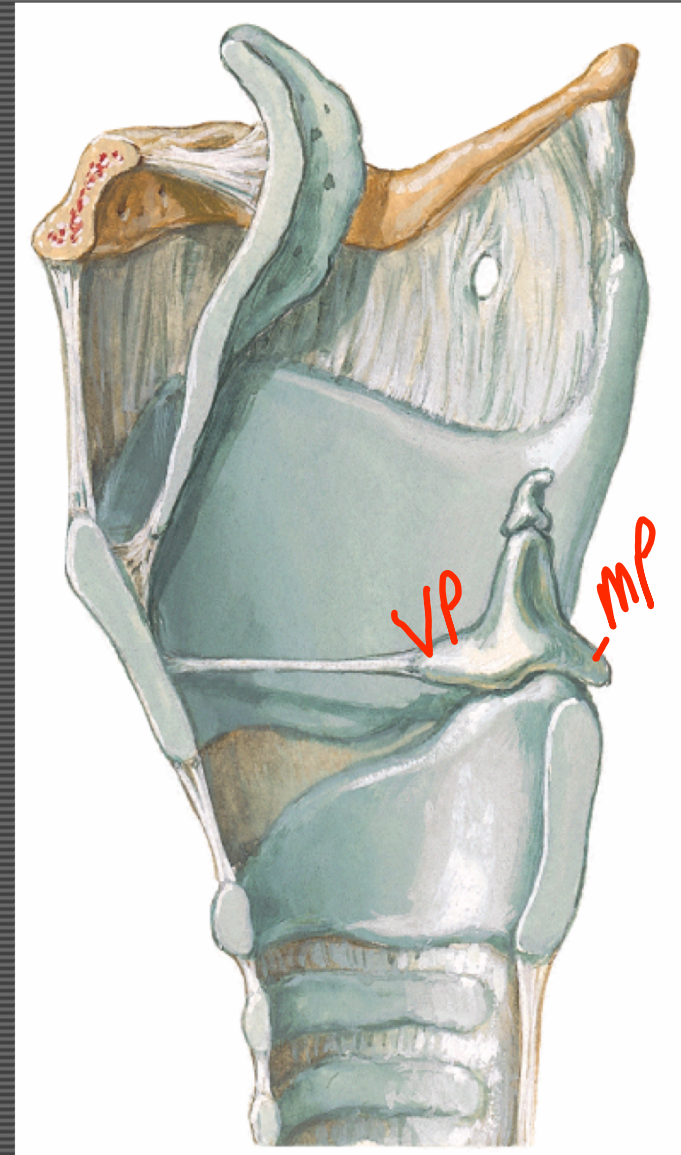
Larynx



Larynx

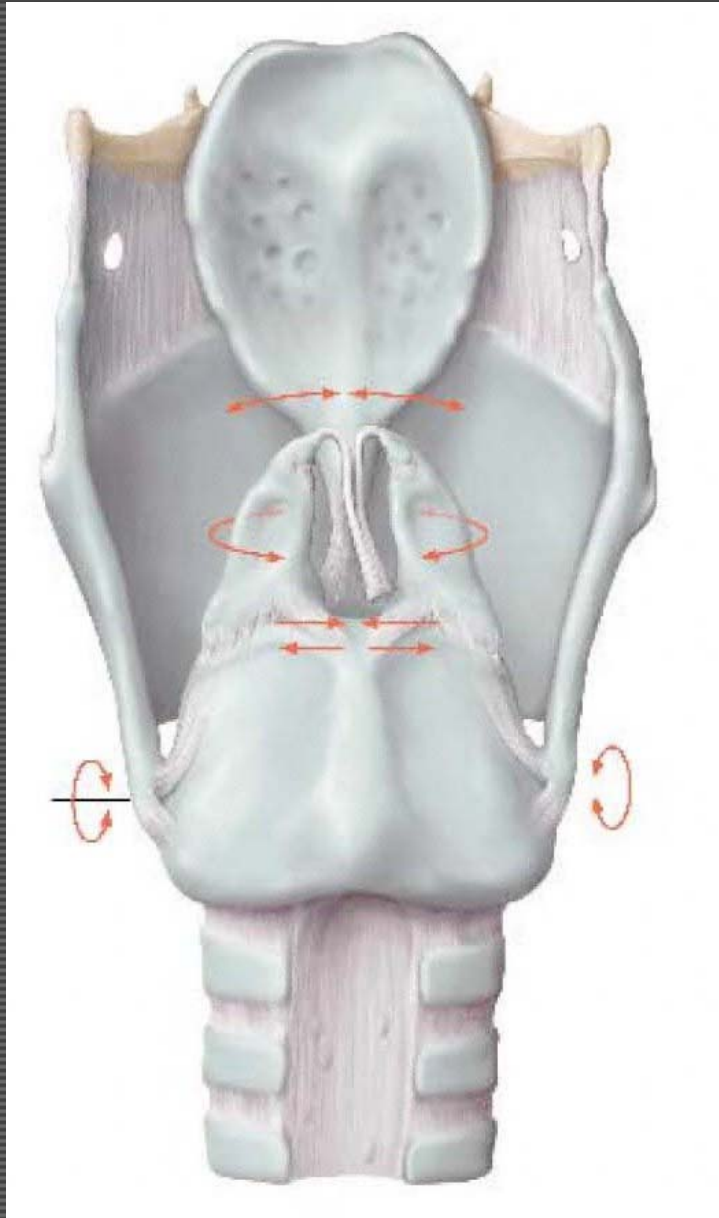


GAFS Fig. 8.186

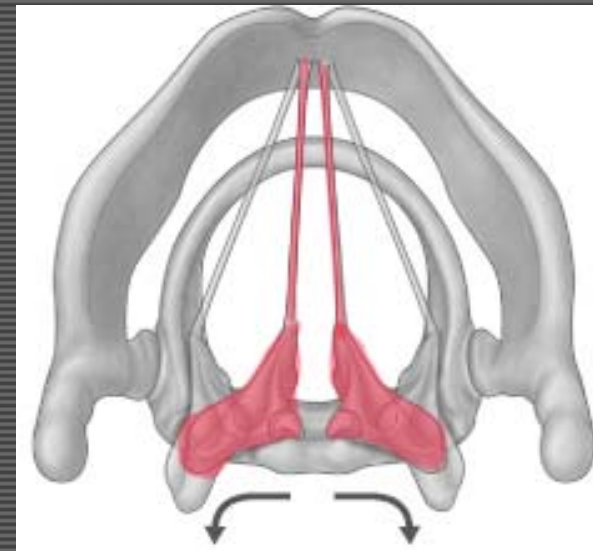
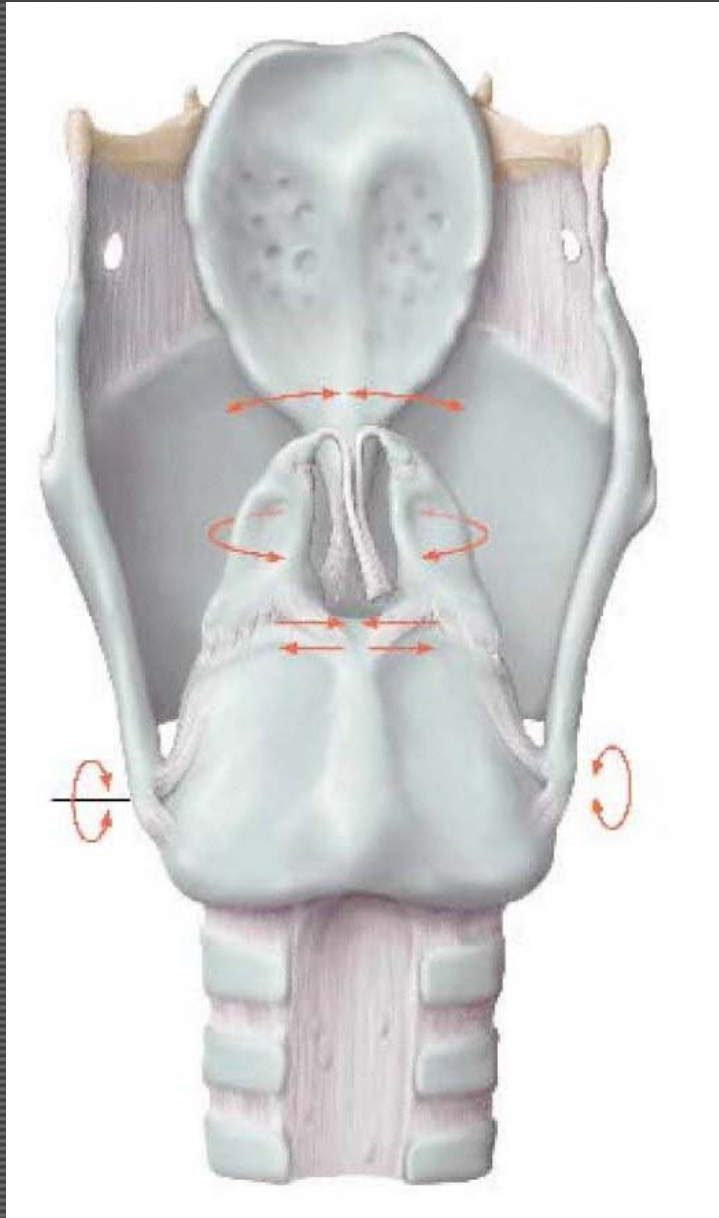


Medial view; Sagittal Section

Movements of the laryngeal cartilages

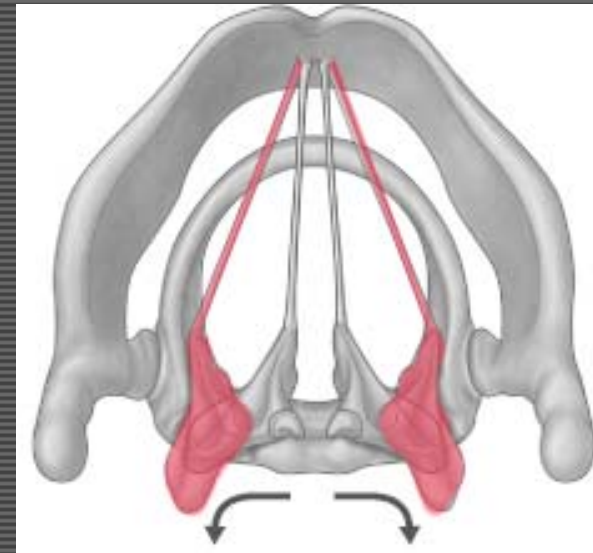
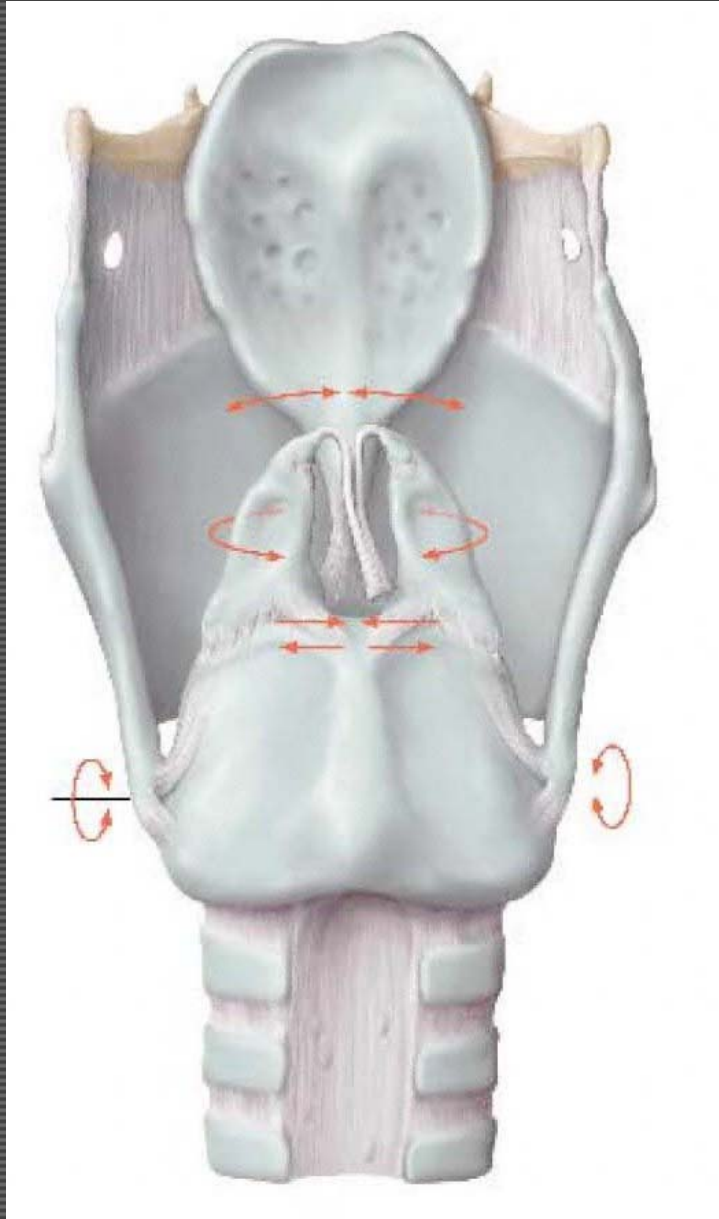


Movements of the laryngeal cartilages



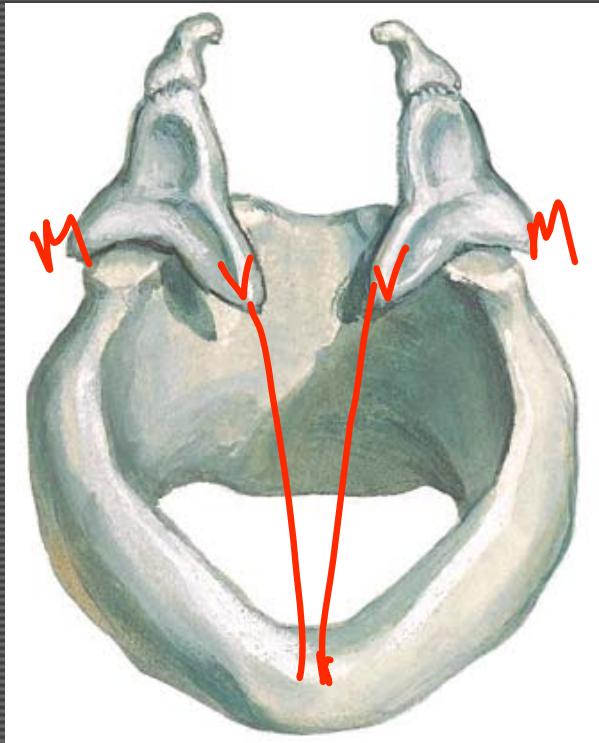
GAFS Fig. 8.207

Movements of the laryngeal cartilages

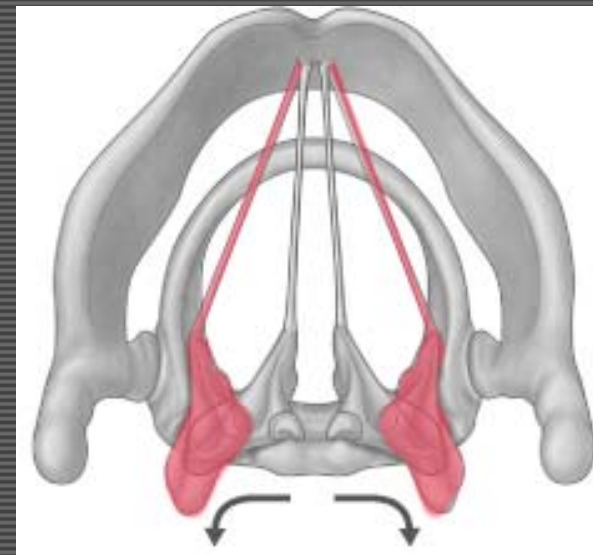


GAFS Fig. 8.207

Movements of the laryngeal cartilages

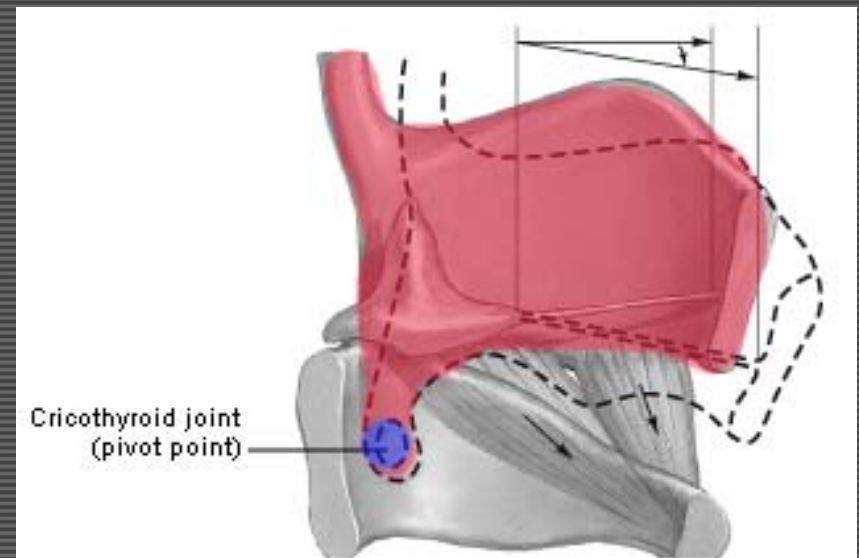
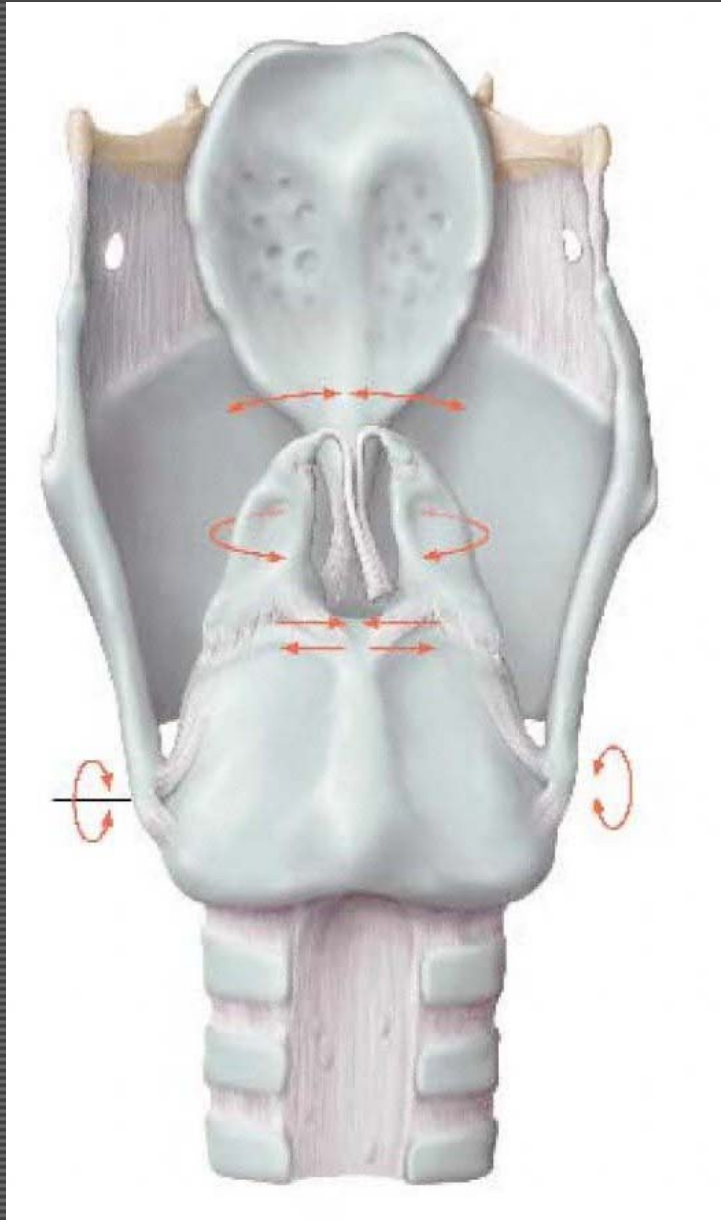


Anterosuperior view

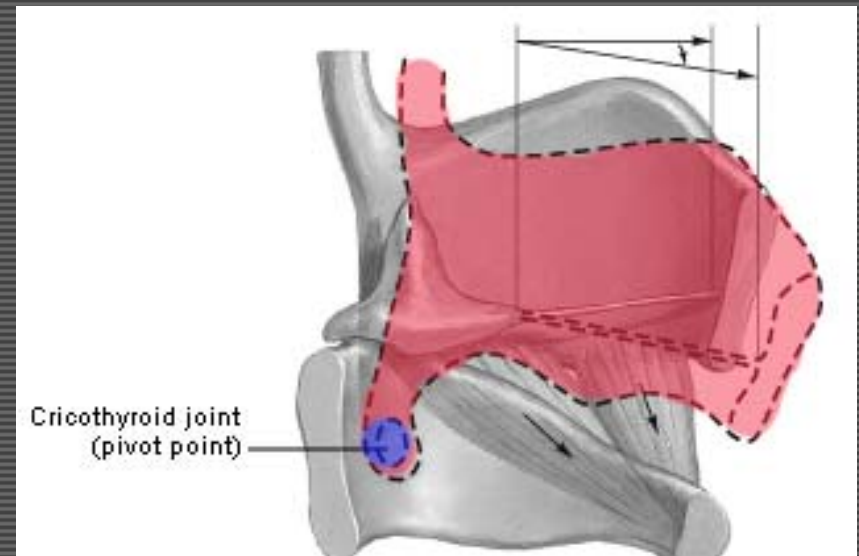
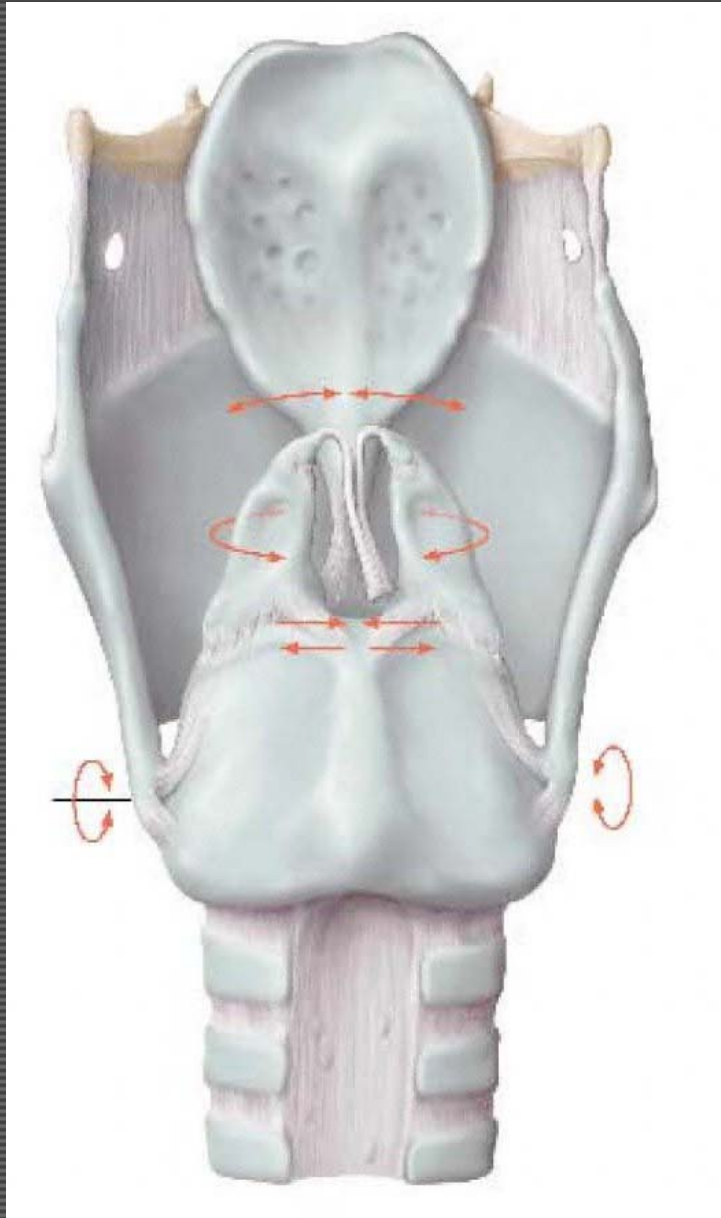


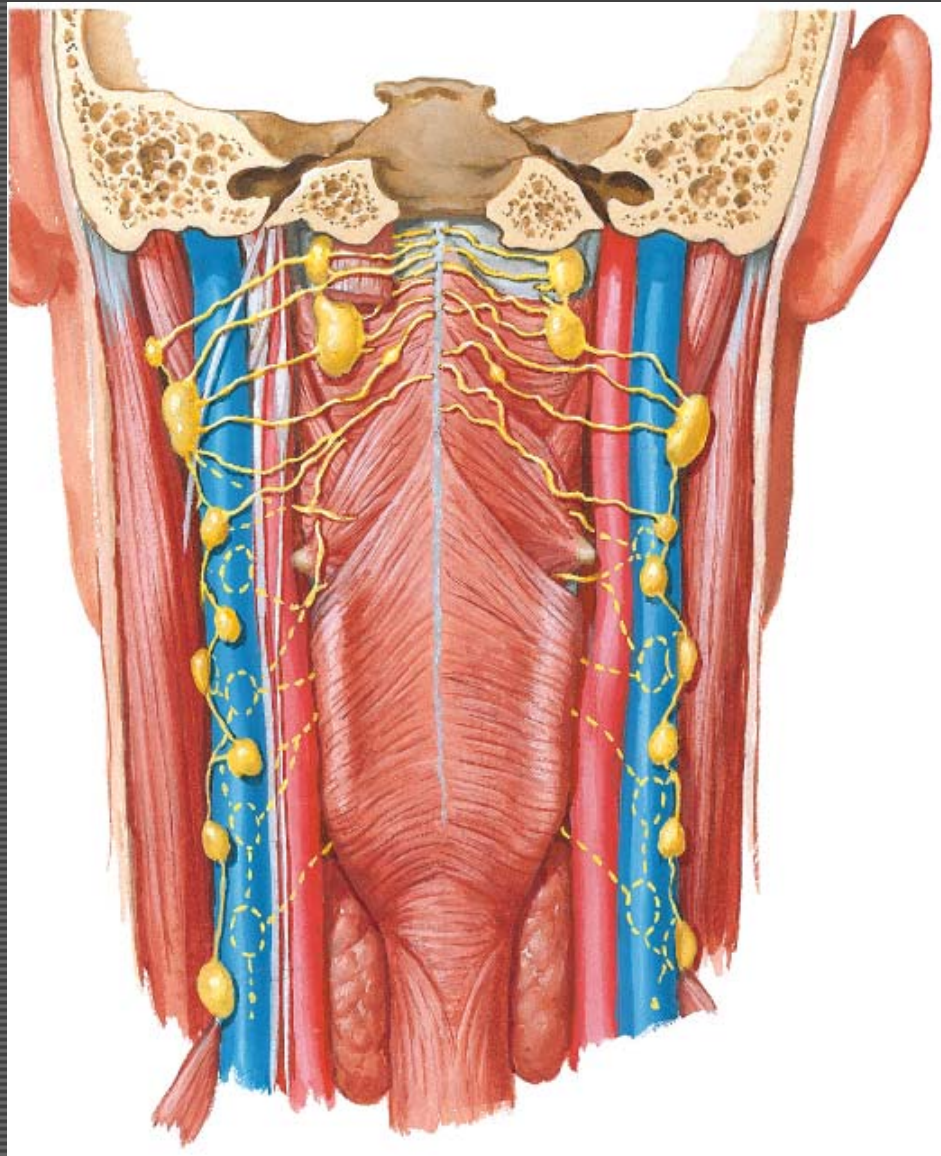
GAFS Fig. 8.207

Movements of the laryngeal cartilages

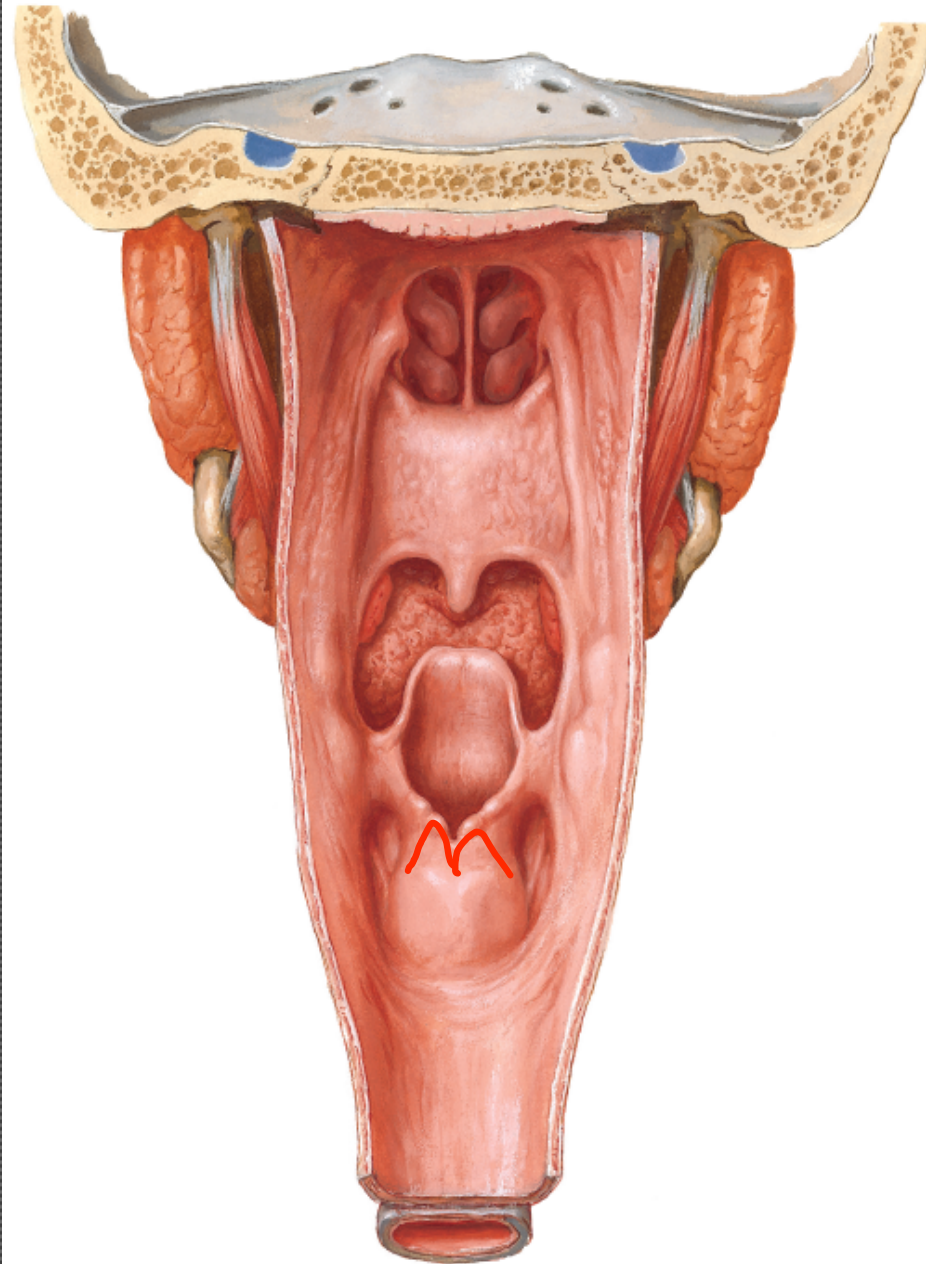


Movements of the laryngeal cartilages

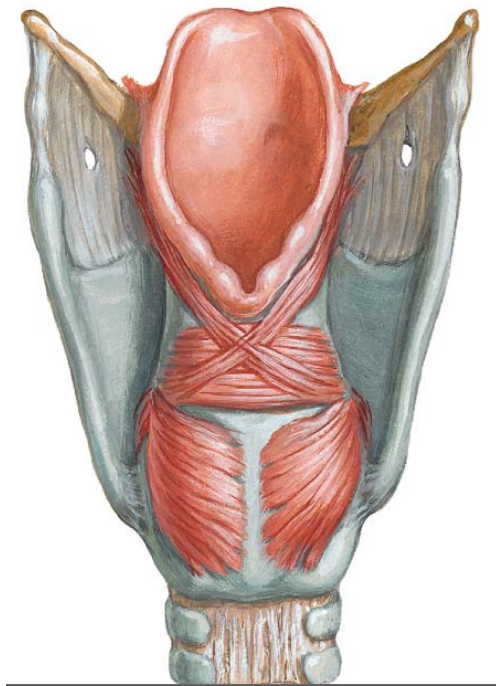
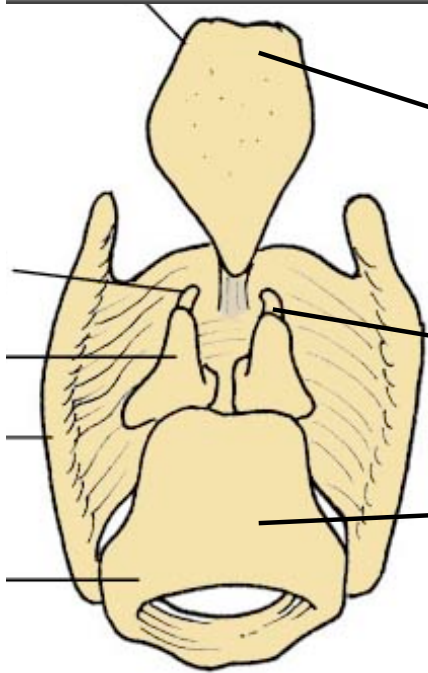
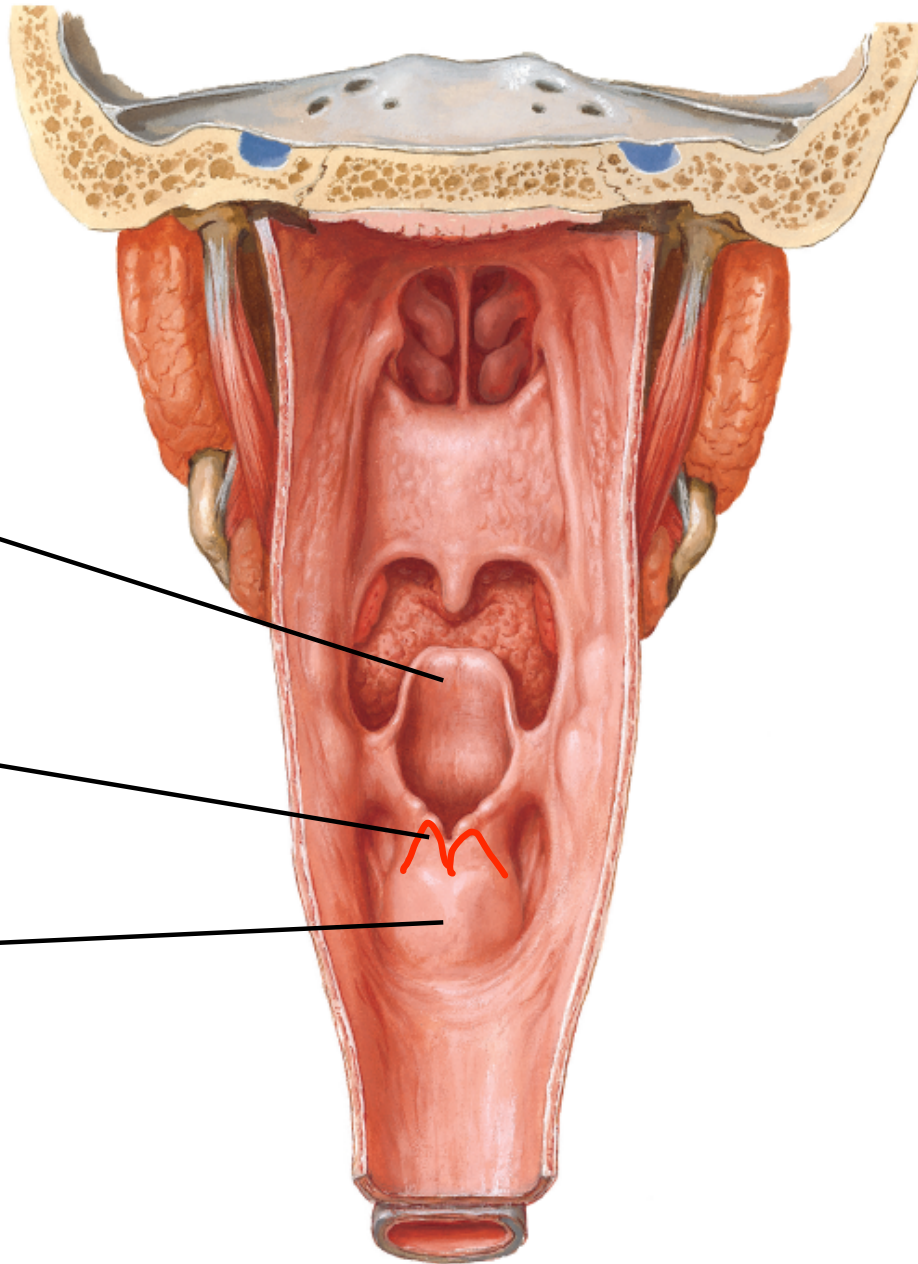




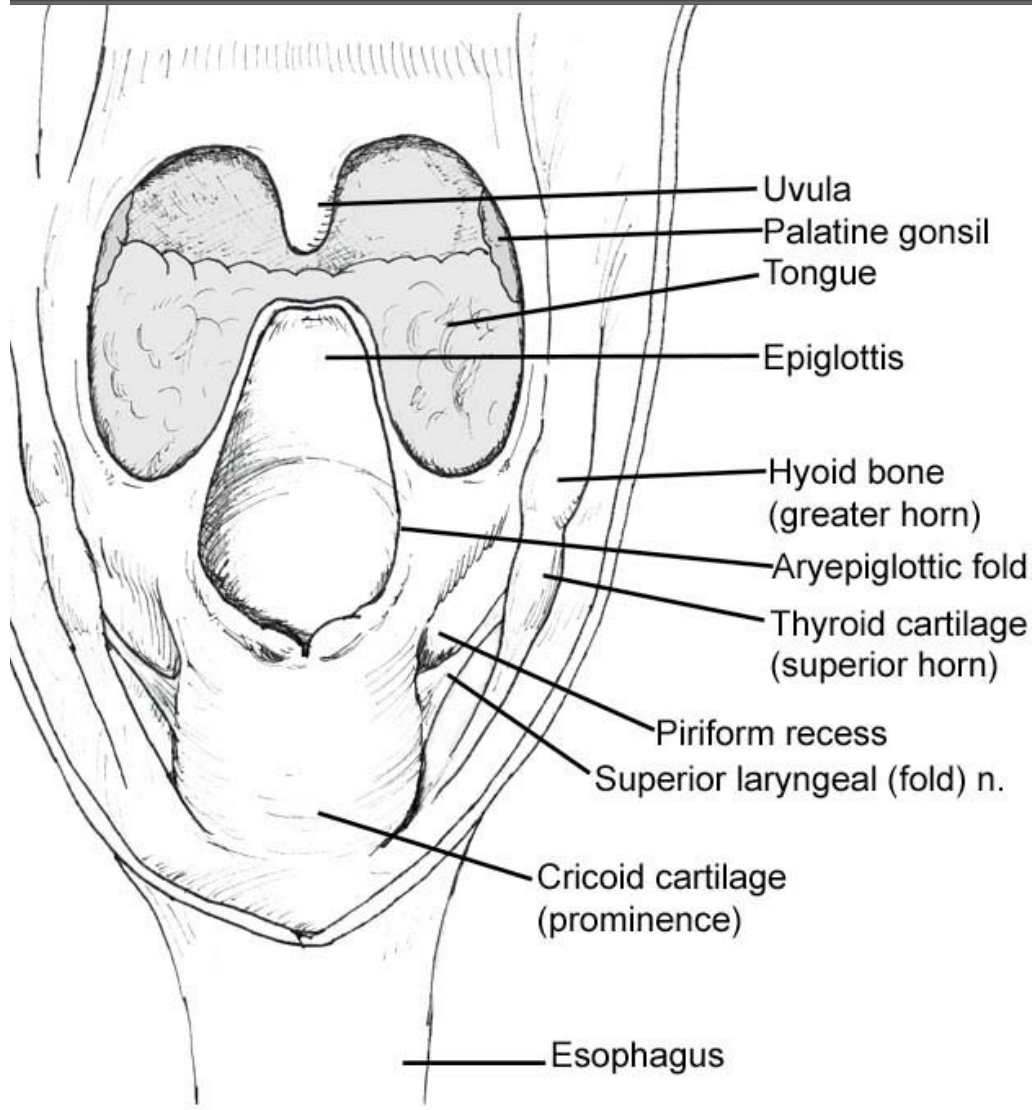
Pharynx: Opened Posterior View



Pharynx: Opened Posterior View

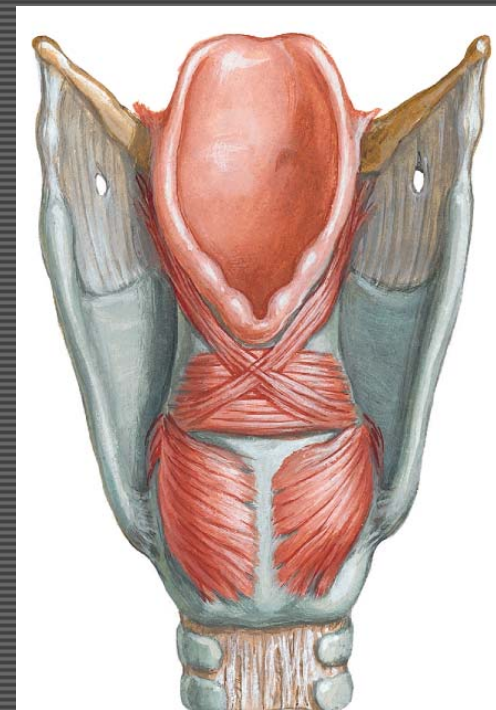


Larynx - Folds



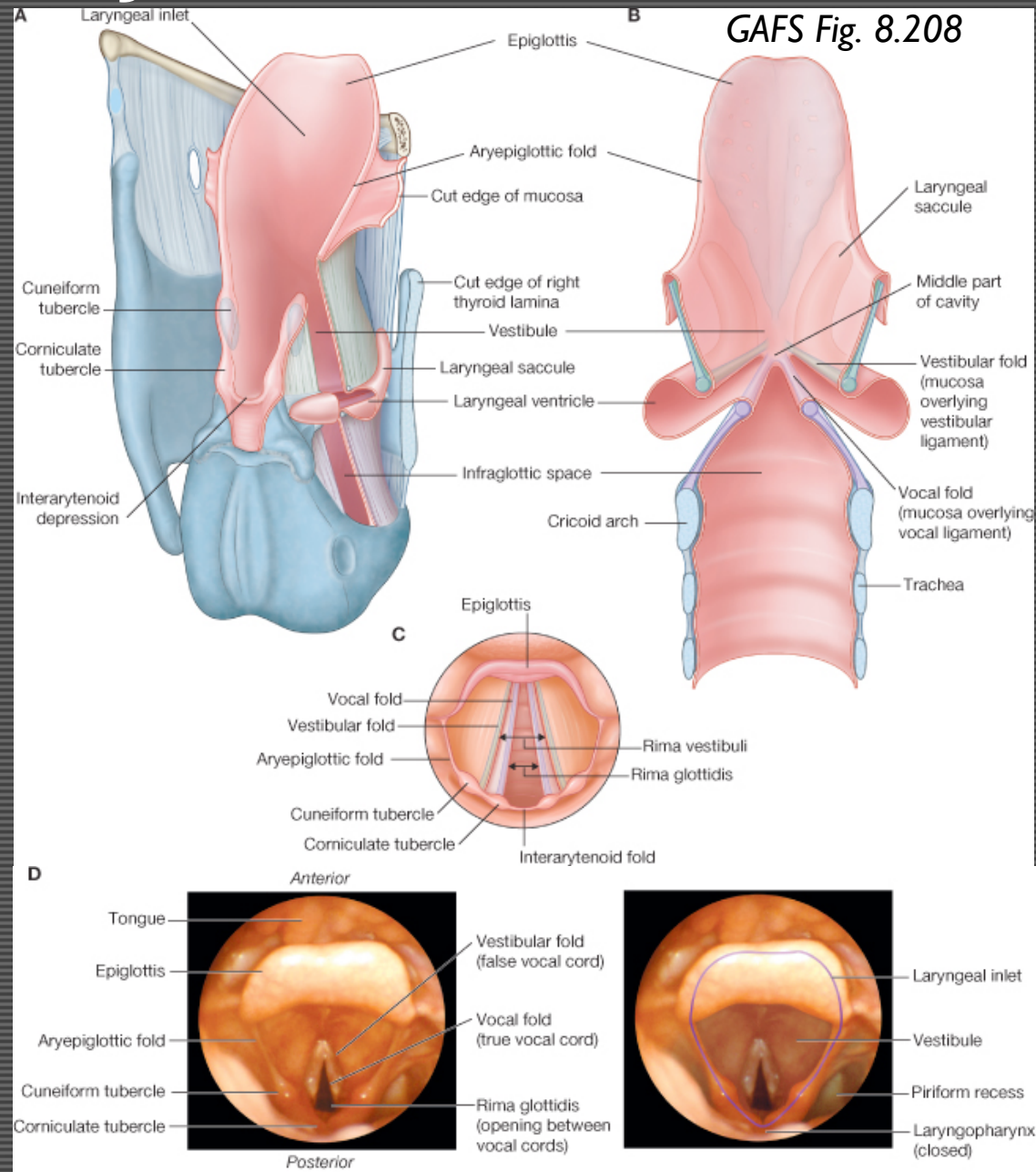
Pharynx - Posterior view
(pharynx opened from behind to show the anterior wall)

Aryepiglottic fold
Vestibular folds
Vocal folds
Ventricle
Rima glottidis

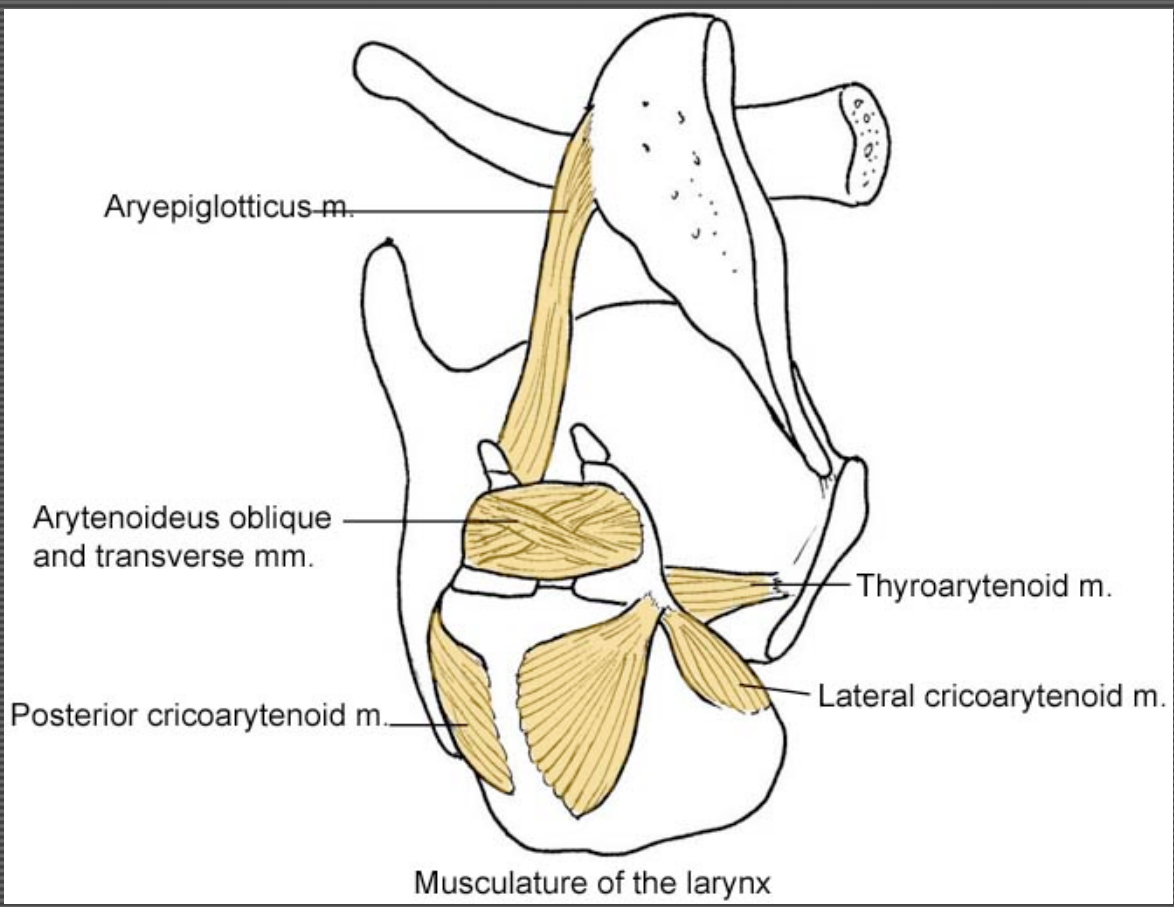


Larynx - Folds

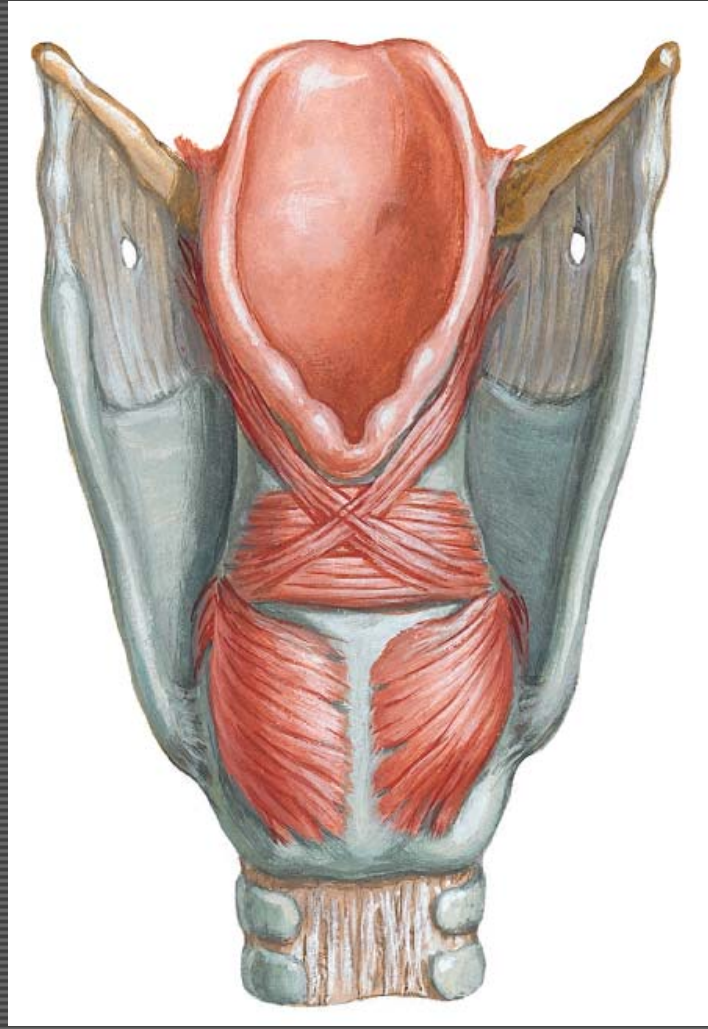
Aryepiglottic fold
 Vestibular folds
 Vocal folds
 Ventricle
 Rima glottidis



Larynx - Muscles

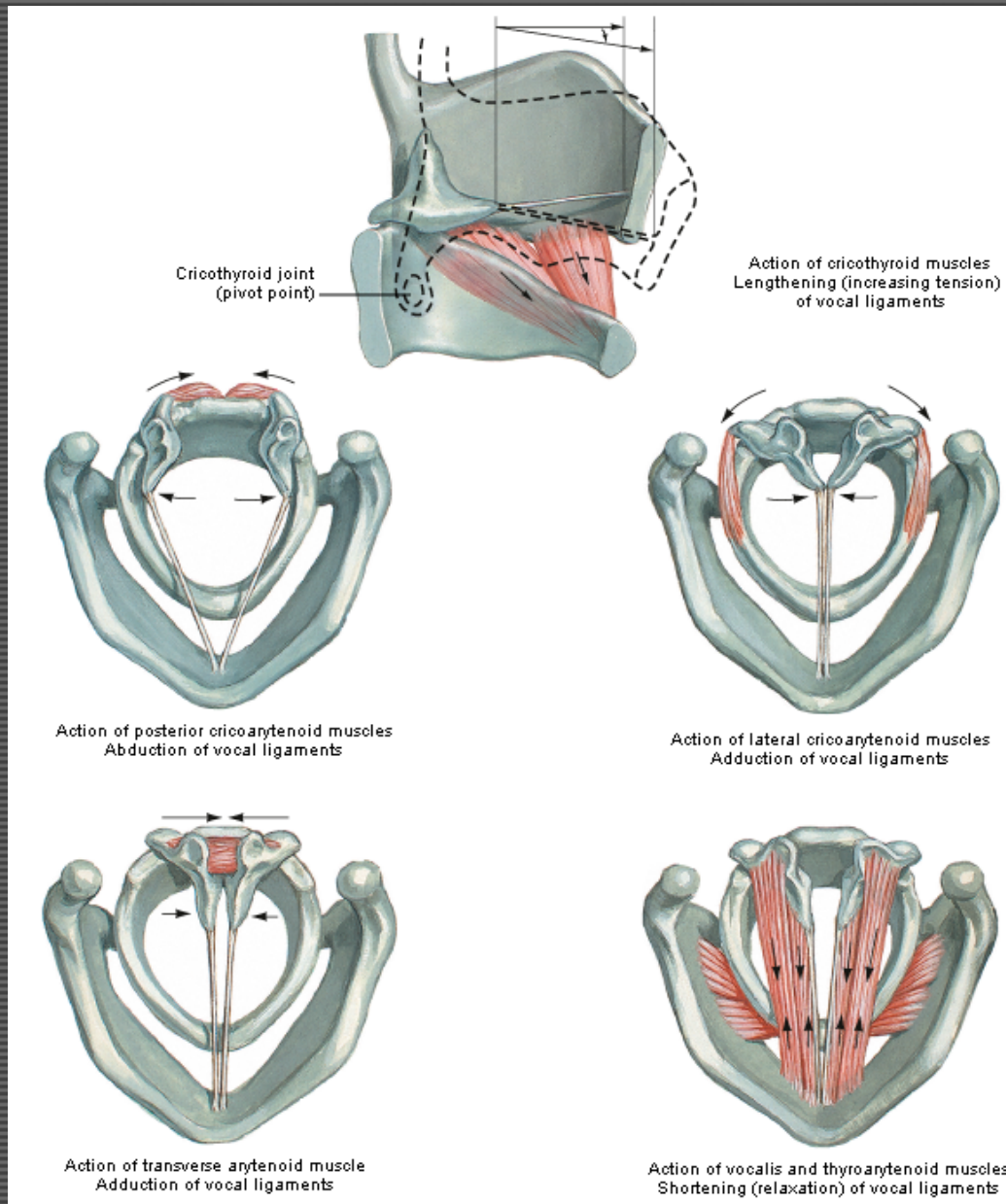


Posterolateral view

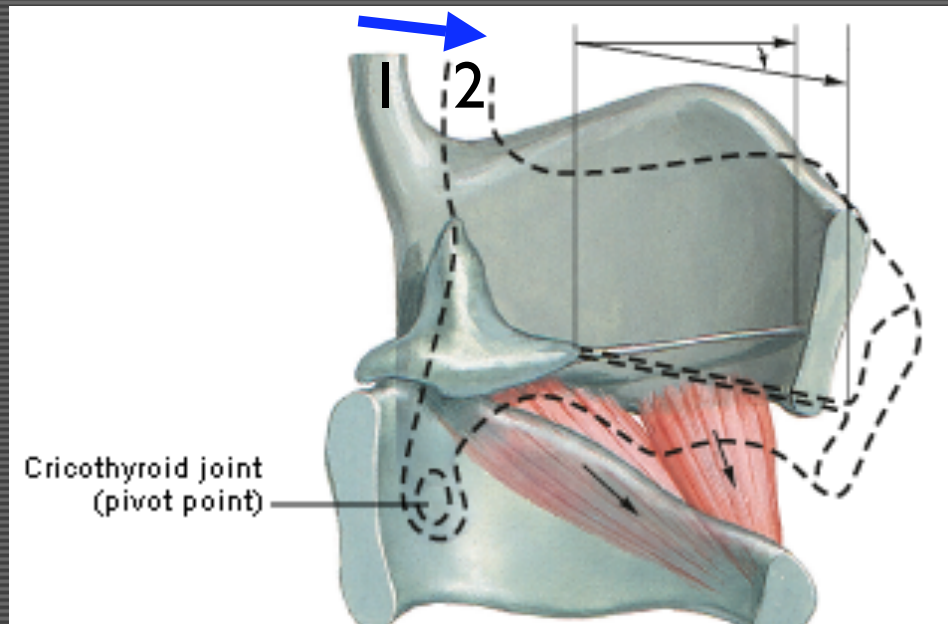


Posterior view

Larynx - Muscles

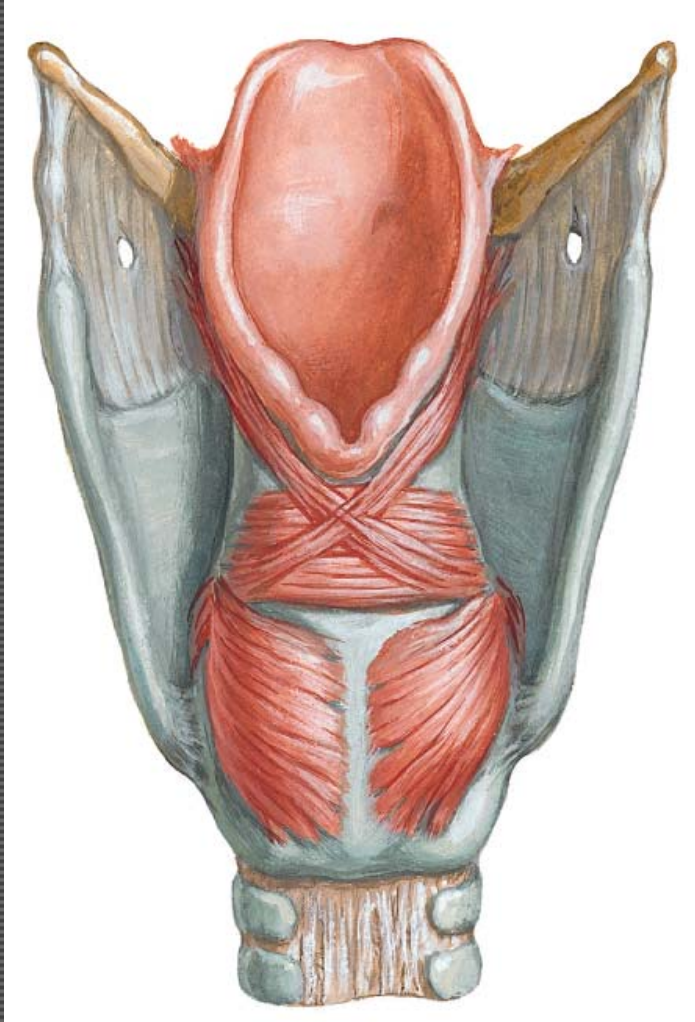


Larynx – Cricothyroid Muscle

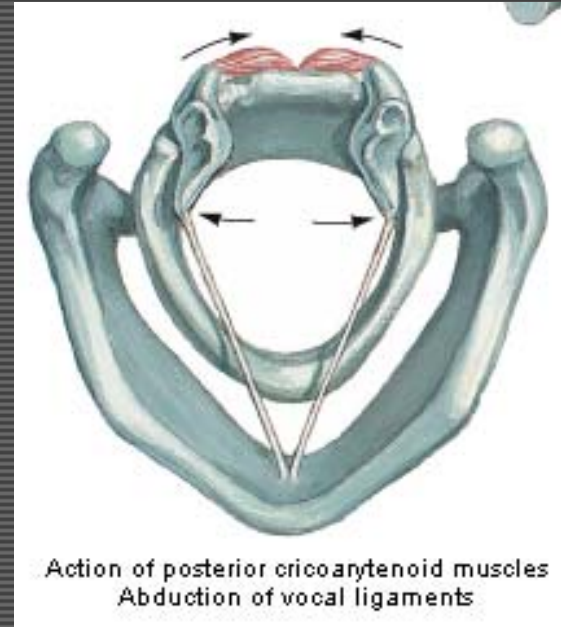


Stretches and tenses vocal cords

Post. Cricoarytendoid m.

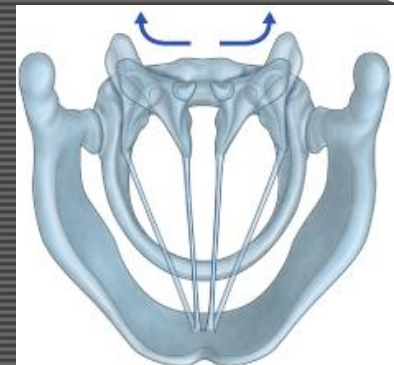


Posterior view

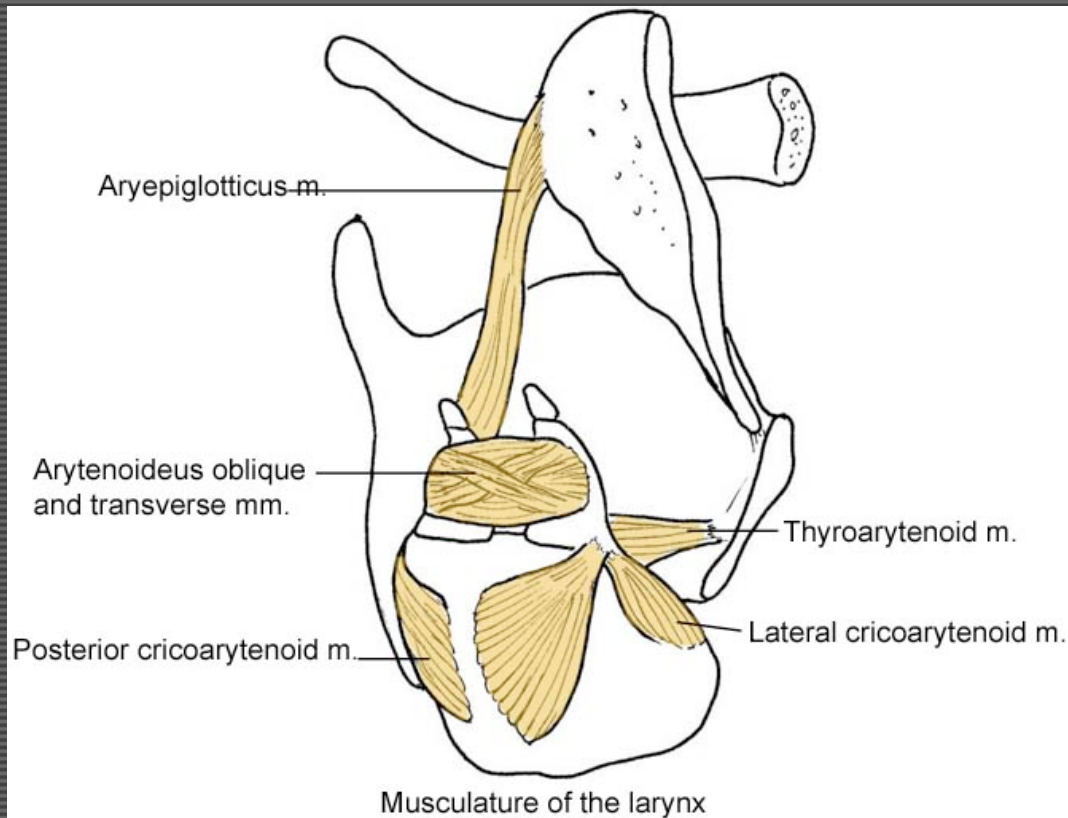


Action of posterior cricoarytenoid muscles
Abduction of vocal ligaments

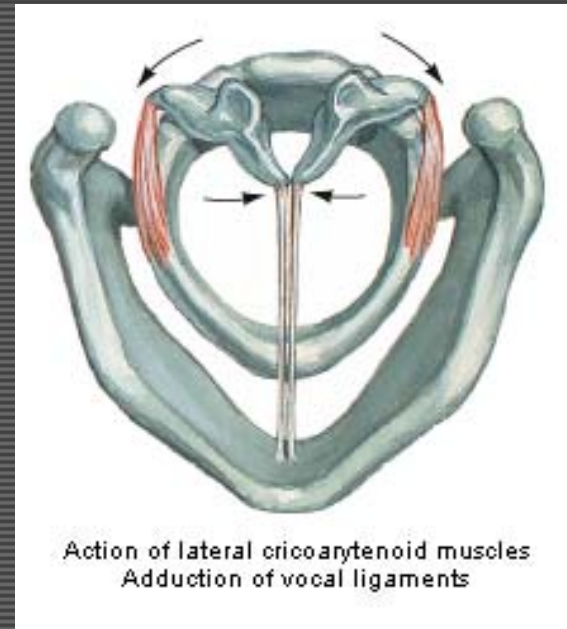
ABducts vocal lig's



Lat. Cricoarytenoid m.

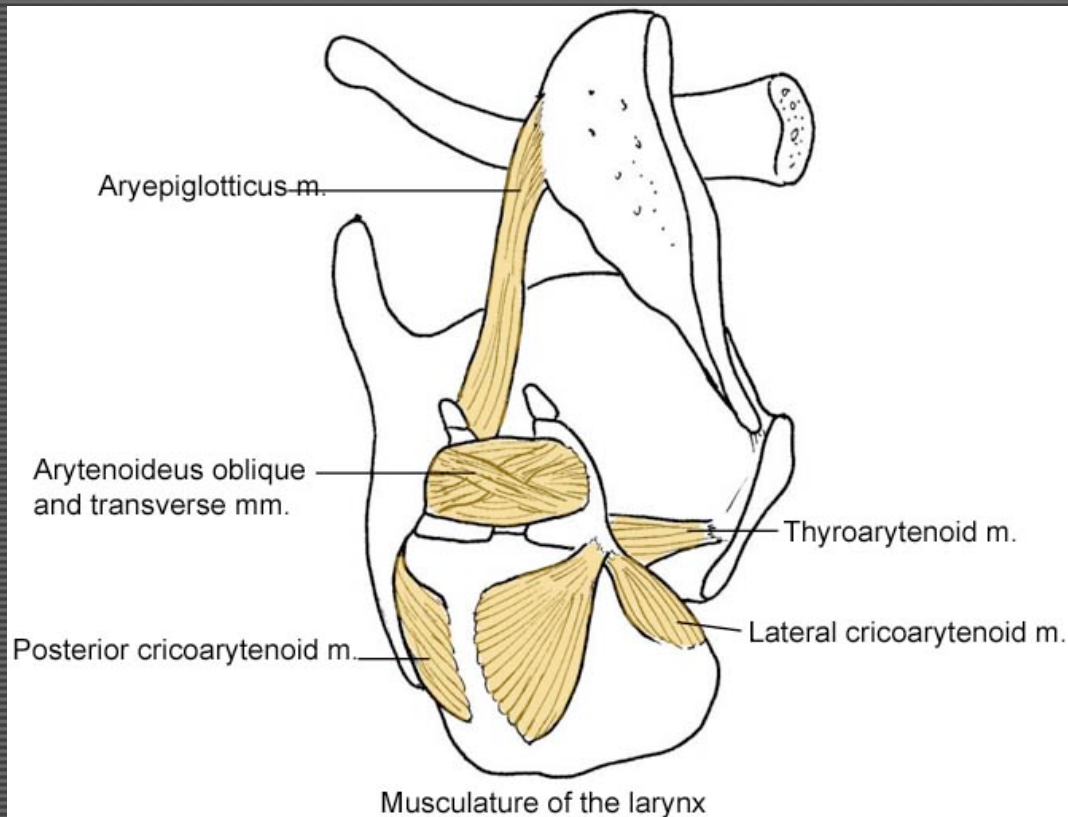


Posterolateral view

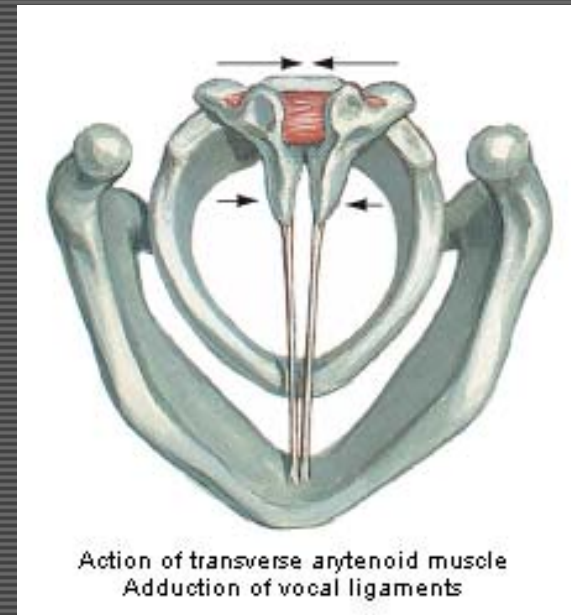


ADDucts vocal lig's

Transv./Obliq. Arytenoid m.

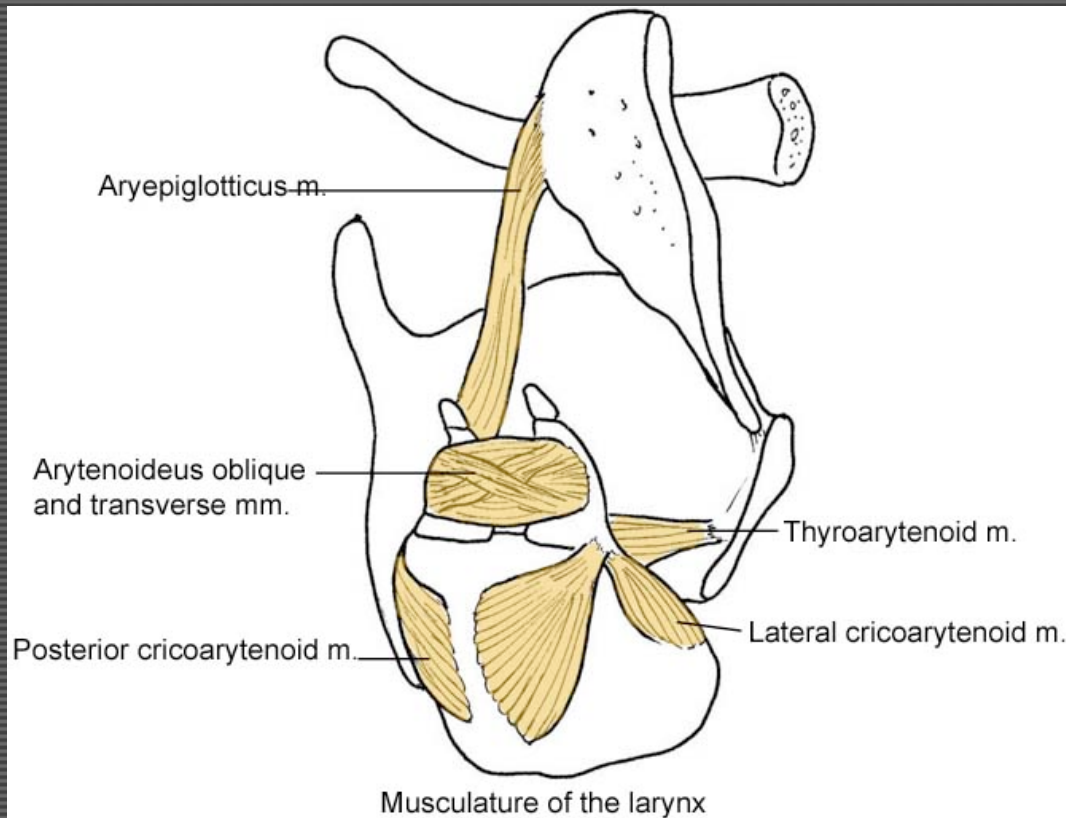


Posterolateral view

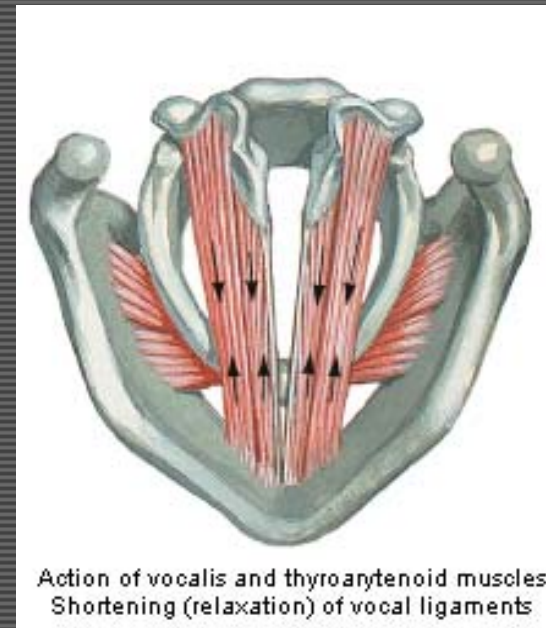


ADDucts vocal lig's

Thyroarytenoid m.

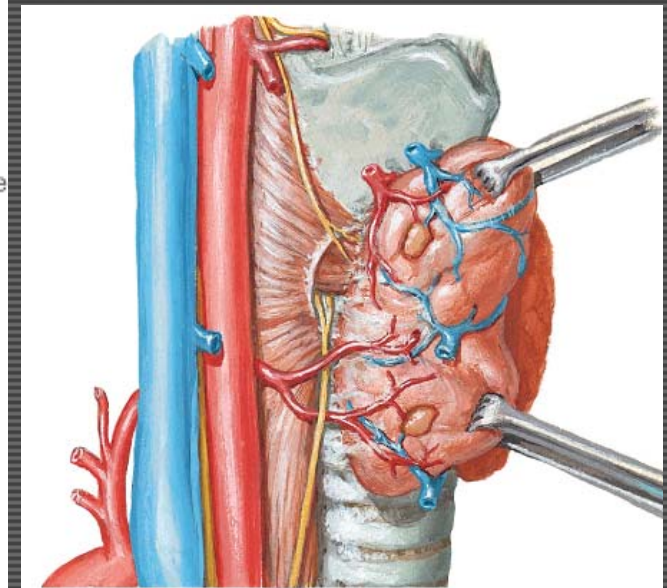
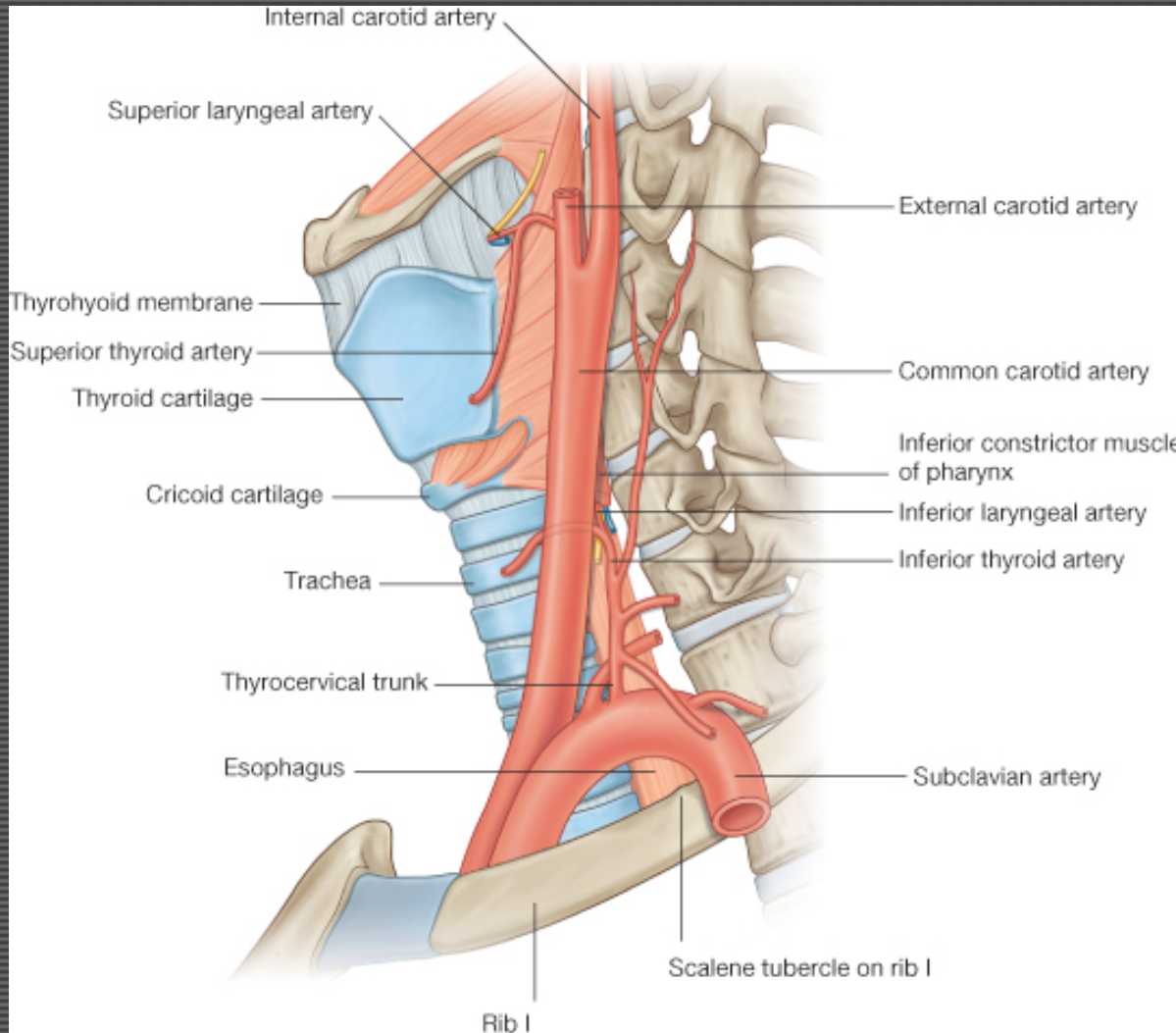


Posterolateral view



Relaxes vocal lig's

Vasculature of the Larynx



GAFS Fig. 8.213

Innervation Review

Tongue muscles:

Innervation Review

Tongue muscles: CN XII (*except* palatoglossus m. ... CN X)

Innervation Review

Tongue muscles: CN XII (*except* palatoglossus m. ... CN X)

Palate muscles:

Innervation Review

Tongue muscles: CN XII (*except* palatoglossus m. ... CN X)

Palate muscles: CN X, (*except* tensor veli palatini ... CN V-3)

Innervation Review

Tongue muscles: CN XII (except palatoglossus m. ... CN X)

Palate muscles: CN X, (except tensor veli palatini ... CN V-3)

Pharyngeal muscles:

Innervation Review

Tongue muscles: CN XII (except palatoglossus m. ... CN X)

Palate muscles: CN X, (except tensor veli palatini ... CN V-3)

Pharyngeal muscles: CN X, (except stylopharyngeus m. ... CN IX)

Innervation Review

Tongue muscles: CN XII (except palatoglossus m. ... CN X)

Palate muscles: CN X, (except tensor veli palatini ... CN V-3)

Pharyngeal muscles: CN X, (except stylopharyngeus m. ... CN IX)

Laryngeal muscles:

Innervation Review

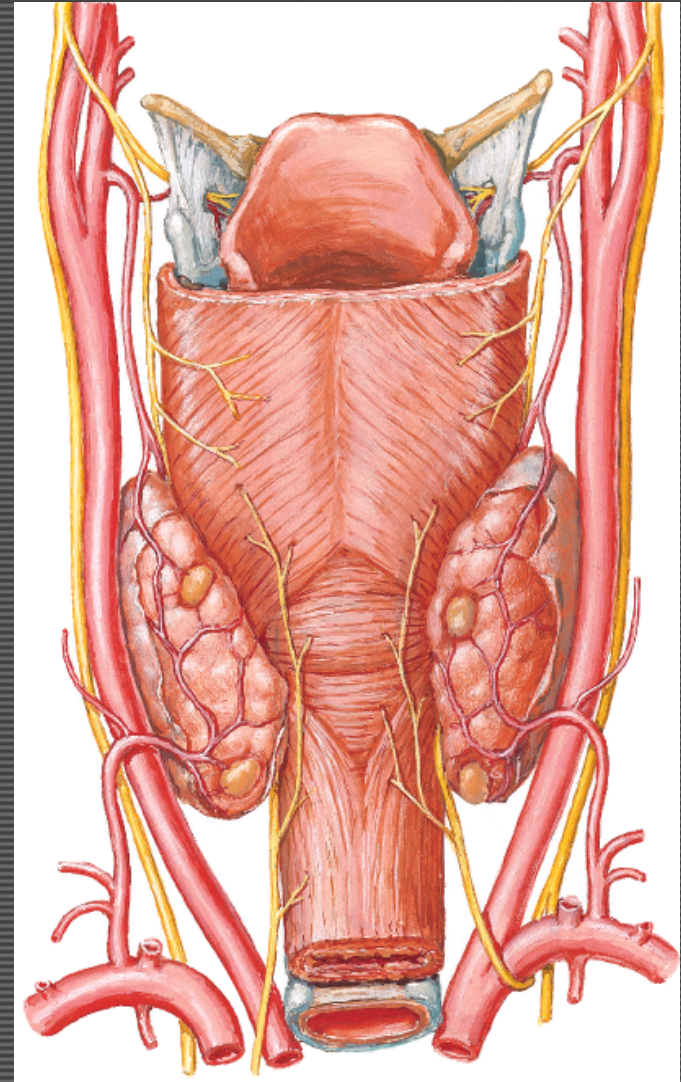
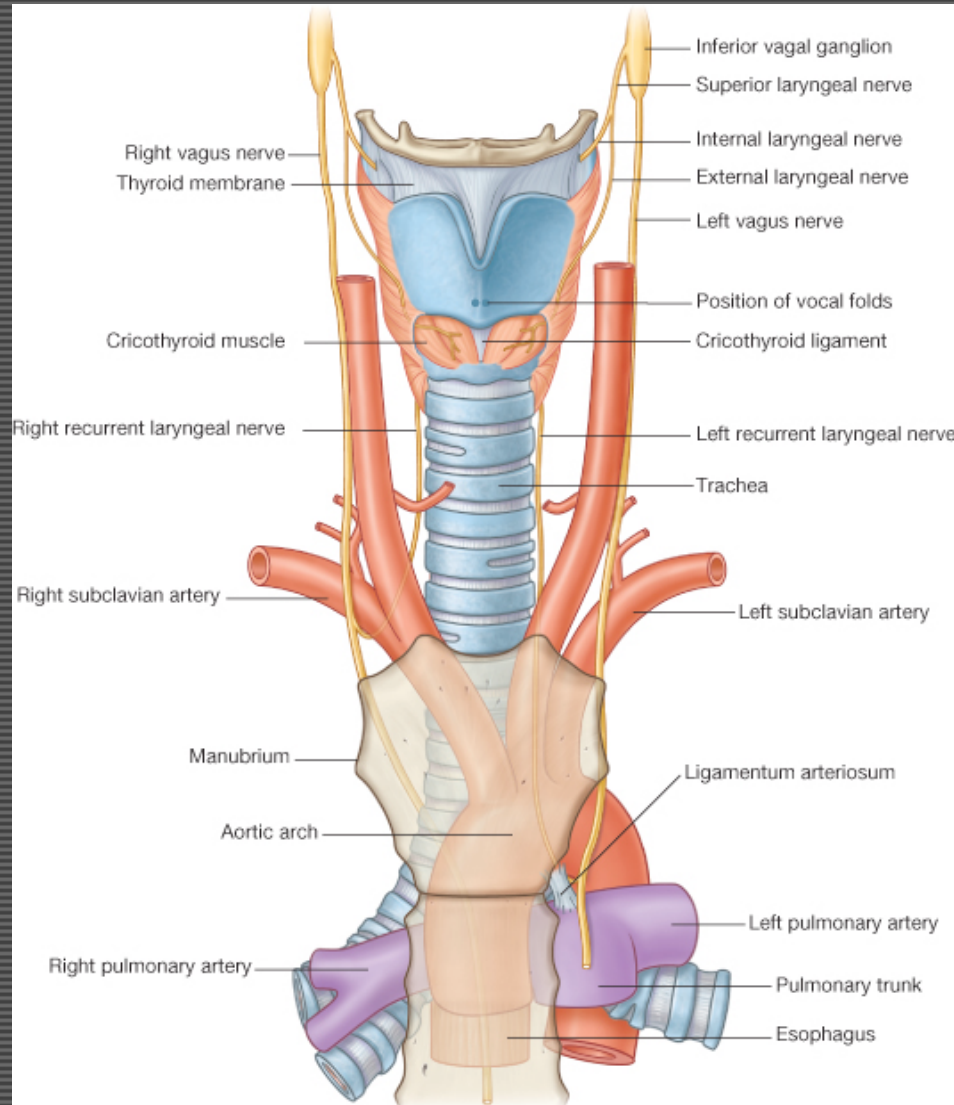
Tongue muscles: CN XII (except palatoglossus m. ... CN X)

Palate muscles: CN X, (except tensor veli palatini ... CN V-3)

Pharyngeal muscles: CN X, (except stylopharyngeus m. ... CN IX)

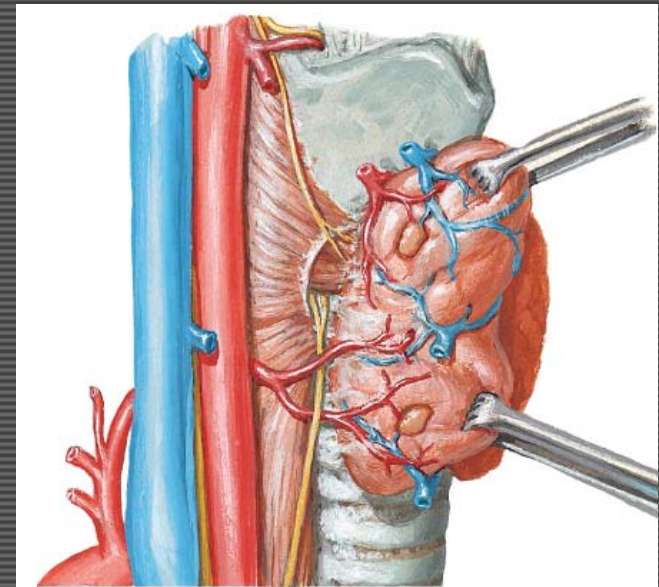
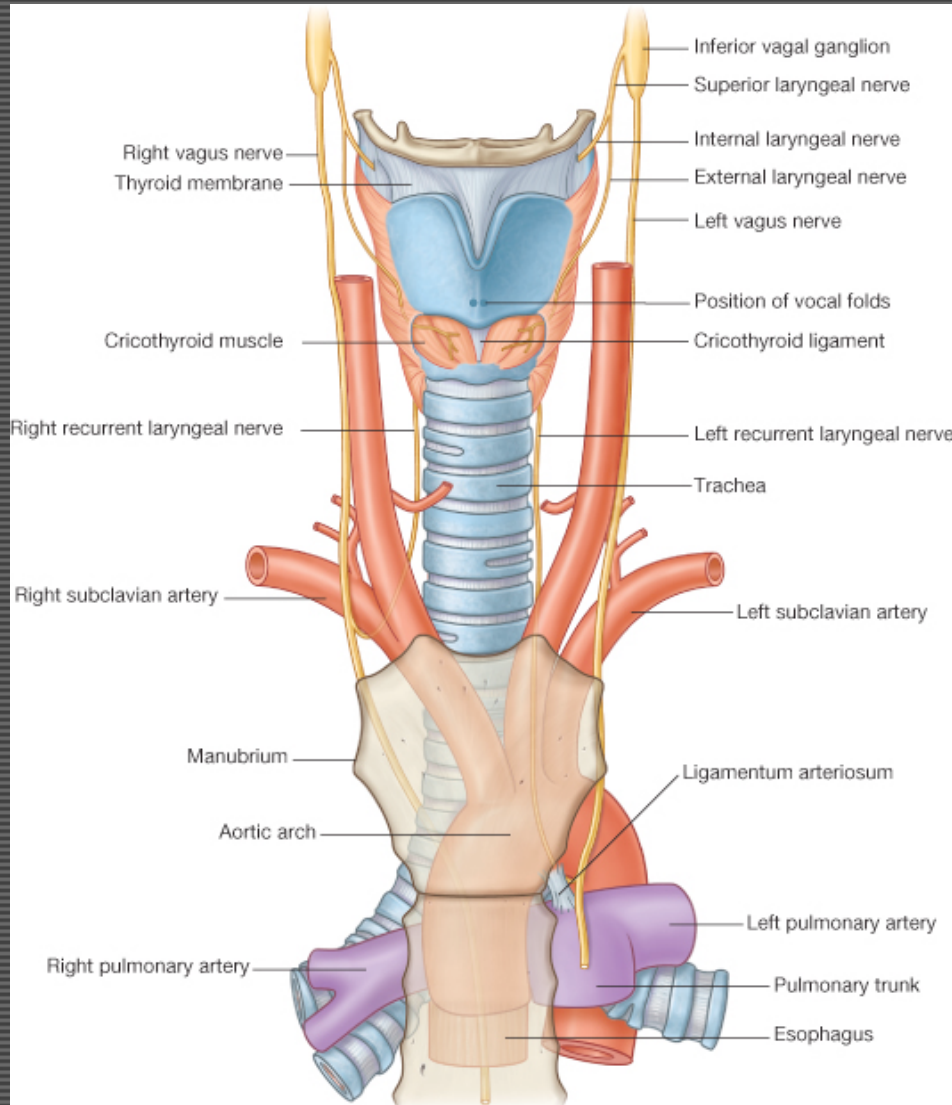
Laryngeal muscles: CN X (recurrent laryngeal n.) {except cricothyroid m. by ext. laryngeal n.}

Innervation of the Larynx

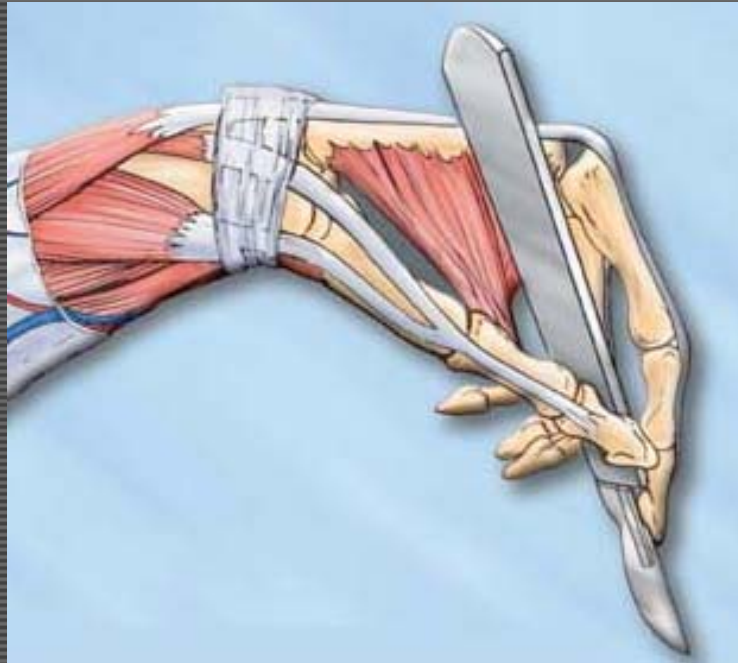


GAFS Fig. 8.215

Innervation of the Larynx



GAFS Fig. 8.215



THANK-YOU